

SURGICAL TREATMENT OF PEDIATRIC SUBPERIOSTEAL ABSCESS SECONDARY TO ACUTE BACTERIAL RHINOSINUSITIS - A CASE REPORT

**Dokić Danijela,¹ Milojević Isidora,² Milenković Aleksandar,¹
Sotirović Jelena,¹ Milojević Milanko,¹ Perić Aleksandar^{1,3}**

¹ Military Medical Academy, Department of Otorhinolaryngology, Belgrade, Serbia

² Centre for Military Medical Institutions, Belgrade, Serbia

³ University of Defense, Medical faculty of the Military Medical Academy, Belgrade, Serbia

Primljen/Received: 15. 04. 2026.

Prihvaćen/Accepted: 16. 05. 2026.

Published Online First: 18. 05. 2026

Abstract: Introduction: Rhinosinusitis, an inflammation of the mucosal lining of the nasal cavity and paranasal sinuses, can be classified by the European Rhinologic Society as acute or chronic, based on the duration of symptoms and signs. Acute bacterial rhinosinusitis (ABRS), caused by bacterial invasion of the nasal and paranasal sinus mucosa, may lead to severe complications if untreated. Among these, orbital complications are the most common, including pre-septal cellulitis, orbital cellulitis, subperiosteal abscess (SPA), orbital abscess, and cavernous sinus thrombophlebitis. They can be associated with visual impairment and intracranial extension. SPA is a rare but serious complication in children. It arises from infection spreading to the subperiosteal space, often following ABRS involving the ethmoid sinuses, due to developmental, anatomical, and immunological factors. Early diagnosis and intervention are critical to prevent long-term sequelae.

Case presentation: A 14-year-old boy presented with complications of ABRS, including progressive right eyelid swelling and impaired ocular mobility. Imaging revealed complete opacification of the right ethmoid and maxillary sinuses with bony erosion of the ethmoidal bony septa and lamina papyracea, but without signs of intracranial extension. Laboratory findings showed elevated white blood cell count, elevated C-reactive protein (CRP), and prior exposure to cytomegalovirus and Epstein-Barr virus, with immunoglobulin G (IgG) levels > 500.00 IU/mL. Despite initial antibiotic therapy with amoxicillin-clavulanic acid and metronidazole, clinical deterioration required a

change in antimicrobial therapy and surgical intervention. Endoscopic sinus surgery (ESS) was performed, successfully evacuating the purulent collection within the SPA, as well as from the ethmoid and maxillary sinuses. Postoperatively, a combination of broad-spectrum intravenous antibiotics, including vancomycin, meropenem, and clindamycin, guided by bacteriological analysis of the pus sample, was administered to target potentially resistant microorganisms, resulting in near-complete resolution of symptoms.

Conclusion: SPA, especially in the pediatric population, requires prompt and aggressive treatment to prevent life-threatening complications. Initial therapy includes intravenous antibiotics, but surgical drainage becomes essential if there is no improvement within 48 hours or if there is impending visual loss. ESS is a safe, minimally invasive technique for managing SPA unresponsive to conservative treatment. Early surgical intervention should be further explored to optimize outcomes and minimize morbidity in pediatric cases.

Keywords: Abscess, Anti-Bacterial Agents, Child, Ethmoid Sinus, Nasal Surgical Procedures, Rhinosinusitis.

INTRODUCTION

According to the European Position Paper on Rhinosinusitis and Nasal Polyps (EPOS) 2020, rhinosinusitis—an inflammation of the mucosal lining of the nasal cavity and paranasal sinuses—is classified by symptom duration into acute (<12 weeks) and chronic (>12 weeks). Acute rhinosinusitis is most of-

Table 1. Chandler's classification of orbital complications of ABRS

Chandler's classification system	
Group I Pre-septal orbital cellulitis	Inflammation and edema anterior to the orbital septum
Group II Post-septal orbital cellulitis	Extension of the inflammation and edema beyond the orbital septum
Group III Subperiosteal abscess	Abscess between the peri-orbit and the bony wall of the orbit
Group IV Intra-orbital abscess	Purulent collection occurs within the orbit
Group V Cavernous sinus thrombophlebitis	Cavernous sinus thrombosis posterior extension through the superior ophthalmic veins

ten viral but may progress to acute bacterial rhinosinusitis (ABRS), with secondary bacterial infection of the nasal and paranasal sinus mucosa. While antibiotics have reduced complications, untreated ABRS can lead to severe osseous, orbital, intracranial, or systemic complications. Orbital complications are the most common, including pre-septal or periorbital cellulitis, orbital cellulitis, subperiosteal abscess (SPA), orbital abscess, and cavernous sinus thrombophlebitis, potentially resulting in visual impairment, optic neuritis, and Brown syndrome (1, 2).

During the 1970s, Chandler et al. (3) introduced a classification scheme for orbital complications that remains widely used today. As presented in Table 1 and Figure 1, Group 3 refers to a subperiosteal abscess (SPA), characterized by the accumulation of pus between the periosteum of the orbital wall and the bony wall separating the ethmoid sinus from the orbit.

A subperiosteal abscess (SPA) is a rare but potentially serious complication of pediatric rhinosinusitis, characterized by the accumulation of purulent material between the periorbita and the underlying ethmoid bone, often resulting from the spread of infection from adjacent structures such as the paranasal sinuses, most commonly through the lamina papyracea. While subperiosteal abscesses can occur in any age group, they are most commonly seen in children and adolescents due to anatomical and immunological factors that increase susceptibility to sinus infections and their complications. In the pediatric population, the ethmoid sinuses, which are the first to pneumatize, are particularly vulnerable to infections that may spread to the orbit. The proximity of the orbit to the paranasal sinuses and the thinner bony structures in children contribute to this increased risk of developing subperiosteal abscesses (3, 4). The immune system is often highly reactive during rapid pubertal development, and the emissary veins connecting the mucosa of the paranasal sinuses, bony compartments, and orbit lack valves,

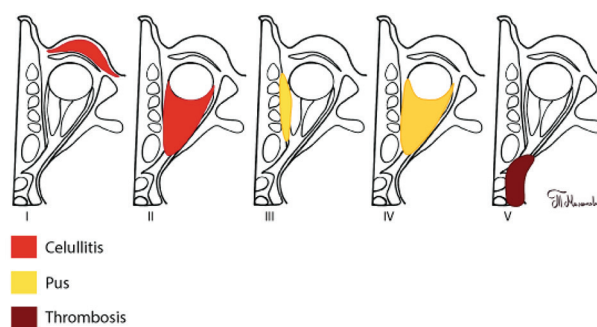


Figure 1. Chandler's classification for orbital complications of ABRS includes pre-septal orbital cellulitis (I), post-septal orbital cellulitis (II), subperiosteal abscess (III), intraorbital abscess (IV), and cavernous sinus thrombophlebitis (V).
Tijana Milenković created this illustration.

(The image is from author's archive.)

allowing retrograde thrombophlebitis and facilitating the spread of infection between these regions (3, 4).

The clinical presentation of subperiosteal abscess in children typically includes fever, rapid-onset unilateral periorbital edema, severe erythema, chemosis (conjunctival swelling), proptosis (bulging of the eye), and restricted ocular movement. Patients often appear toxic, with high fever, severe pain on eye movement, and potentially decreased vision (5). However, symptoms may vary in severity depending on the extent and progression of infection. Early diagnosis and prompt treatment are crucial to prevent complications that may lead to permanent vision loss and intracranial extension (5).

By understanding the complexities and nuances of subperiosteal abscesses in children, healthcare providers can optimize patient outcomes and reduce the risk of long-term complications. Through a thorough review of the available literature and recent advancements in the field, this paper aims to contribute to the ongoing discussion on best practices for diagnosing

and managing this potentially life-threatening condition in pediatric patients.

CASE PRESENTATION

A 14-year-old male with no significant medical history was transferred on April 15, 2024, to a tertiary care center from a secondary care facility due to clinical deterioration during hospitalization for rhinosinusitis. Several days before initial admission, the patient developed nasal congestion, impaired nasal breathing, and high fever, with temperatures reaching 39 °C. Treatment with azithromycin (0.5 g for three days), along with a topical decongestant (xylometazoline 0.05%), was prescribed in primary care. As symptoms did not resolve and the condition worsened, the patient bypassed secondary care and was referred directly to tertiary pediatric care.

Following admission to the pediatric hospital, he developed progressive swelling of the right upper and lower eyelids, accompanied by restricted ocular mobility. The patient received intravenous antibiotic therapy with metronidazole (0.5 g, three times daily) and amoxicillin-clavulanic acid (1.2 g, three times daily). However, the response to therapy was insufficient, and the patient was transferred to our institution.

Investigations and imaging

Upon evaluation in our emergency department on April 22, a routine otorhinolaryngological examination revealed warm edema and hyperemia of the right upper eyelid. Anterior rhinoscopy and rigid endoscopic examination (Karl Storz endoscope, 0°) detected thick purulent discharge in the right nasal cavity, particularly in the middle nasal meatus, also observed draining into the oropharynx.

Urgent contrast-enhanced multi-slice computed tomography (MSCT) of the paranasal sinuses revealed a localized, encapsulated lesion involving the right middle nasal meatus, right ethmoid cells (anterior and posterior), the entire right maxillary sinus, and the medial orbit, located between the periorbita, lamina papyracea, and the remaining bony wall of the ethmoid sinus (Figures 2, 3, 4). The right frontal recess and sinus showed soft-tissue opacification. The lesion demonstrated erosion of the bony structures of the medial orbital wall. No abnormalities of the skull base were observed, and there was no evidence of intracranial extension (Figures 2, 3, 4).

Ophthalmological examination showed no impairment of visual acuity or color vision; however, diplopia was present, along with reduced and painful ocular mobility. Neck ultrasound identified enlarged reactive lymph nodes bilaterally, predominantly on the right side along the major vascular axis.

Given the clinical presentation and radiological findings, the patient was admitted to our Department of Otorhinolaryngology on April 23, 2024, for further management. Although the illness initially presented as an upper respiratory tract infection, it rapidly progressed, prompting further laboratory evaluation. Results showed leukocytosis ($14.21 \times 10^9/L$) and elevated C-reactive protein (CRP) levels (95 mg/L).

In consultation with an infectious disease specialist, serological testing for cytomegalovirus and Epstein-Barr virus was performed, both showing positive IgG antibodies (> 500.00 IU/mL; reference positivity > 1 IU/mL), consistent with past exposure.

Given the patient's age and lack of response to initial therapy, empirical parenteral antibiotic treatment was initiated preoperatively as recommended by the infectious disease specialist: vancomycin (1 g/12 h),

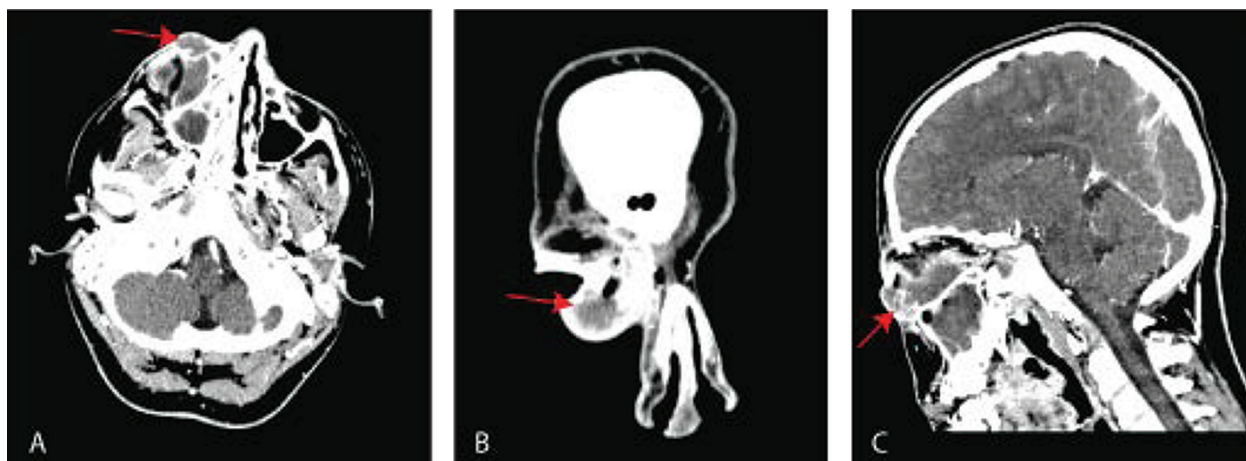


Figure 2. MSCT of the paranasal sinuses with contrast injection in axial (A), coronal (B), and sagittal (C) planes shows an opacification of anterior and posterior ethmoid cells, right maxillary sinus, medial orbital wall, and right frontal recess (red arrow). (The image is from author's archive.)

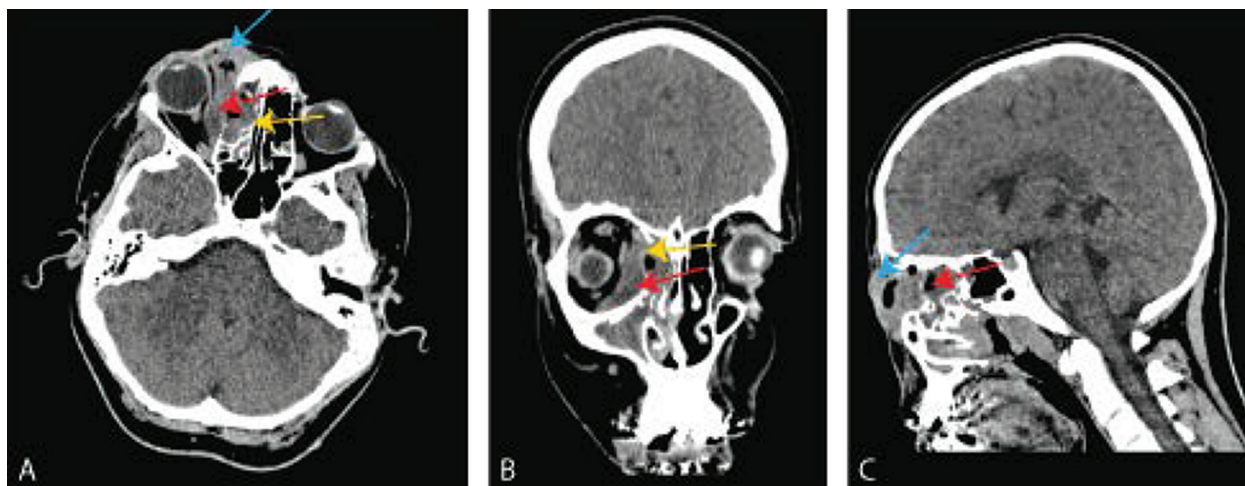


Figure 3. Axial (A) and sagittal (C) planes reveal eyelid edema and cellulitis (blue arrow). Axial (A) also shows soft tissue opacification in the ethmoid sinuses, suggesting inflammation or infection (yellow arrow). Coronal (B) highlights partial dehiscence of the medial orbital wall with pus accumulation in the medial part of the right orbit (yellow arrow). (The image is from author's archive.)

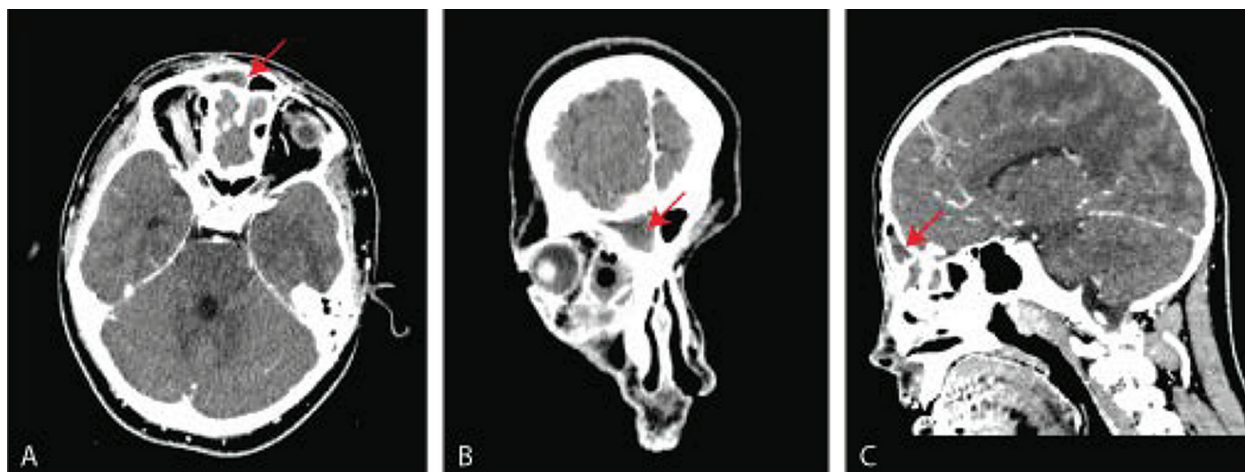


Figure 4. MSCT of the paranasal sinuses, evaluated in axial (A), coronal (B), and sagittal (C) planes, demonstrates opacification of the right frontal sinus shown by the arrow. (The image is from author's archive.)

meropenem (1 g/8 h), and clindamycin (600 mg/8 h). Adjunct therapy included xylometazoline nasal drops (0.1%, three times daily in both nostrils) and mometasone furoate nasal spray (50 µg, two puffs in both nostrils, twice daily).

Blood cultures were obtained due to concern for systemic involvement and clinical deterioration, and all results were negative. Procalcitonin levels were elevated (35 ng/mL), while D-dimer was also elevated (5 ng/mL). B-scan ultrasonography of the right eye revealed an abscess measuring 22.98 mm in diameter.

Given diplopia, restricted ocular movement, and imaging-confirmed abscess formation, the patient was urgently scheduled for endoscopic surgical treatment.

Surgical treatment

On April 24, under general anesthesia, following adequate visualization and mucosal decongestion, a

septoplasty was performed to optimize the surgical corridor for endoscopic access. Under endoscopic guidance, an uncinectomy was initially performed, resulting in the release of thick, yellow, trapped secretions from the right maxillary sinus. Similar purulent material was observed upon opening the anterior and posterior ethmoid cells and accessing the frontal recess. Exploration of the medial orbital wall revealed a complete absence of the lamina papyracea. A fluctuating abscess was identified, and an incision of the periorbita was made, yielding purulent content consistent with that obtained during the uncinectomy. Swabs for aerobic and anaerobic bacteria cultures were collected.

Postoperative care

Bacterial culture showed growth of *Haemophilus influenzae*, *Staphylococcus aureus*, and anaerobic *Fusobacterium necrophorum*. Following surgical

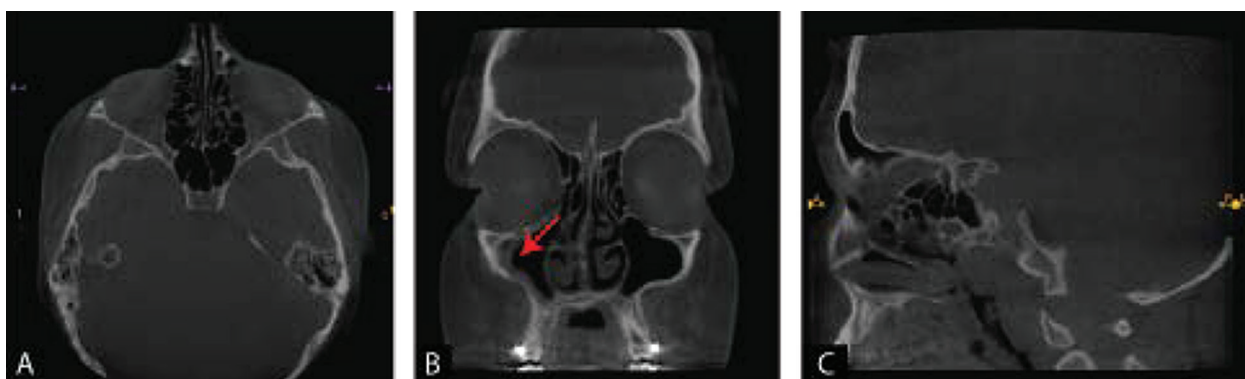


Figure 5. Postoperative CBCT of the paranasal sinuses, evaluated in axial (A), coronal (B), and sagittal (C) planes, demonstrates relatively normal postoperative anatomy (A, C). Note a focal soft tissue thickening within the right maxillary sinus, as indicated by the arrow (B). (The image is from author's archive.)

drainage, the patient was treated with the previously noted parenteral antibiotic therapy (vancomycin, meropenem, clindamycin) for 7 days in consultation with the specialist of infectious diseases, and supportive management (intranasal decongestant drops, mometasone-furoate nasal spray). The patient demonstrated consistent daily improvement, both clinically and in laboratory parameters. Postoperatively, a follow-up B-scan ultrasonography of the eye was performed, which showed an intact ocular bulb with no signs of abscess formation. At the time of discharge, laboratory results were within normal reference ranges, and the patient was afebrile. The patient was discharged from the clinic in good general condition, with the recommendation to take cefuroxime tablets 500 mg, two times daily, and metronidazole tablets 400 mg, three times daily, for another 5 days.

Outpatient follow-up

Upon discharge, the patient experienced an uneventful recovery, reporting no complaints during regular monthly follow-ups. Clinical examinations consistently revealed normal findings. A cone beam computed tomography (CBCT) scan performed six months postoperatively confirmed the expected postoperative status, with mild mucosal thickening in the right maxillary sinus but no evidence of the prior condition (Figure 5).

DISCUSSION

Although rare, SPA is a serious condition due to its potential for severe ophthalmologic and neurologic complications. Despite its rarity, SPA is clinically significant, as it is both preventable and treatable when promptly addressed.

A notable feature in our patient was the lack of clinical improvement despite early antibiotic therapy. An increased titer of IgG antibodies to cytomegalo-

virus and Epstein–Barr virus indicates that the immune status of the patient was probably previously impaired by these viruses, which may have contributed to a weak response to the initial antibiotic therapy. To that, it should be added that the level of resistance of bacterial strains to azithromycin, especially in the post-COVID era, is very high. The diagnosis of ABRS and subsequent SPA was established based on a combination of clinical findings and confirmed through CT imaging. We agree with Deutsch et al. (6) that diagnosing SPA solely based on clinical presentation is challenging, especially in pediatric patients, where signs of deterioration may not become evident until considerable damage has already occurred. CT scans, with approximately 80% accuracy in detecting SPA, remain the gold standard for visualizing bony structures (7, 8). Magnetic resonance imaging (MRI) serves as a valuable adjunct by offering superior soft tissue detail and early detection of intracranial complications, although CT remains the preferred initial modality due to its widespread availability.

We anticipated certain bacterial pathogens from the intraoperative swab, as described in a narrative review of the literature by Werner et al. (9), which identified *Streptococcus anginosus*, *Staphylococcus aureus*, and group A *Streptococcus* as the most commonly isolated microorganisms, with methicillin-resistant *Staphylococcus aureus* (MRSA) reported in 9% of cases by Burek et al. (10). These studies emphasize the importance of anaerobic microorganisms in the pathogenesis of orbital complications. Despite their relatively frequent occurrence, anaerobes are often not detected due to inadequate sampling of purulent content; they die upon exposure to oxygen and therefore cannot be demonstrated. Consequently, we continued broad-spectrum antibiotic therapy without modification, given the patient's progressive clinical and laboratory improvement, especially after a prior clinical decline observed during treatment with intra-

venous metronidazole and amoxicillin-clavulanic acid in the initial phase of hospitalization. The pathogenesis of SPA involves bacterial spread through valveless venous plexuses, direct extension via neurovascular foramina, or dehiscent orbital walls (11, 12). In our case, *Fusobacterium necrophorum* was also isolated among the bacteria, which is now considered one of the important pathogens in orbital complications of ABRS (13). Previously, anaerobic microorganisms were rarely reported as causes of these complications. This is less the case today, due to improved sampling of purulent material from the paranasal sinuses and orbital abscesses. It is essential to immediately place the swab in transport medium to avoid exposure to oxygen, which can lead to loss of anaerobic viability (13).

As McDermott et al. (14) note, the management of orbital complications of ABRS is heterogeneous, with no definitive surgical indications for early-stage disease, except in rare cases where vision is at risk, while SPA, orbital abscess, and intracranial extension are well-established indications for surgery. We argue that early surgical drainage not only allows for abscess culture but also aids in identifying the causative microorganism, facilitating targeted antimicrobial therapy. In addition, ensuring ventilation of the pneumatic spaces enables the eradication of anaerobes by exposure to oxygen. This strategy supports judicious and effective antibiotic use, optimizing treatment outcomes by tailoring therapy to the specific infection. While external surgical approaches have traditionally been favored, endoscopic sinus surgery (ESS) has emerged as a less invasive and highly effective alternative (13, 14, 15). Authors from Graz University Hospital (15, 16) demonstrated the success of ESS in managing ABRS with orbital complications, particularly for abscesses located medially or inferomedially. In our case, since the abscess was located inferomedially, ESS was performed to remove edematous and inflamed mucosa, open the sinus drainage pathways, and facilitate effective evacuation of purulent content. ESS provides substantial benefits, including avoidance of facial scarring, effective abscess drainage, and restoration of sinus ventilation, thereby reducing the risk of recurrence (15, 16). Our case underscores the importance of early recognition, appropriate imaging, and a combined medical–surgical approach in managing SPA, ensuring optimal outcomes while minimizing complications.

The study by Santos et al. (17) shows that most patients with SPA can improve with careful monitoring and conservative treatment. Neurological symptoms, the patient's overall clinical condition, the degree of proptosis, pain or limitation of eye movements, and worsening laboratory findings are key factors in

assessing the need for surgical intervention. Similarly, Tzelnick et al. (18) point out that children who do not respond to conservative treatment or who present with established abscess formation often require surgery. In recurrent cases where the cause is not clear, elective surgery or prophylactic antibiotics should be considered. These studies highlight the need for tailored treatment plans and close monitoring to achieve the best outcomes. We agree with the literature, including Cantone et al. (19), that worsening symptoms within 48 hours despite appropriate antibiotics is a clear indication for surgical intervention in children with orbital complications.

CONCLUSION

Prompt and effective treatment is critical to prevent complications. While intravenous antibiotics are typically the first line of management, surgical drainage of the orbit and affected sinuses becomes essential if there is no significant improvement in the patient's overall condition. For medial or medial-inferior abscesses, timely surgical intervention often yields favorable outcomes. ESS offers a safe and effective, minimally invasive approach for managing SPA. We should bear in mind that anaerobes are an important factor in the development of these complications. Therefore, it is important to collect pus samples appropriately. Further research is needed to evaluate the potential benefits of earlier surgical intervention using ESS to improve outcomes in this complex condition.

Acknowledgement: We extend our gratitude to Tijana Milenković, graphic engineer, for her expertise in editing the media content (Figure 1).

Funding: This research received no external funding or sponsorship.

Conflict of Interest Statement: The authors declare that there is no conflict of interest related to this paper.

Author Contribution & Responsibilities: The authors take full responsibility for the accuracy and integrity of the content, as well as the validity of institutional affiliations. The publisher remains neutral regarding jurisdictional claims in institutional affiliations. All authors have read and agreed to the published version of the manuscript. All authors contributed equally to the writing of this paper.

Consent for Publication: The patient gave written consent for the publication of his case and images.

Note: Artificial intelligence was not used in this study.

Licensing: This work is licensed under a Creative Commons Attribution 4.0 International (CC BY 4.0) License.

Sažetak

HIRURŠKO LEČENJE DEČJEG SUBPERIOSTALNOG APSCESA KAO KOMPLIKACIJE AKUTNOG BAKTERIJSKOG RINOSINUZITISA – PRIKAZ SLUČAJA

Đokić **Danijela**,¹ Milojević Isidora,² Milenković Aleksandar,¹
Sotirović Jelena,¹ Milojević Milanko,¹ Perić Aleksandar^{1,3}

¹ Vojnomedicinska akademija, Odeljenje za otorinolaringologiju, Beograd, Srbija

² Centar vojnomedicinskih ustanova, Beograd, Srbija

³ Univerzitet odbrane, Medicinski fakultet Vojnomedicinske akademije, Beograd, Srbija

Uvod: Rinosinuzitis, zapaljenje sluznice nosa i paranazalnih sinusa, klasifikuje se, prema smernicama Evropskog rinološkog udruženja, na akutni i hronični, prema dužini trajanja simptoma i znakova. Akutni bakterijski rinosinuzitis (ABRS), izazvan bakterijskom infekcijom sluznice nosa i paranazalnih sinusa može dovesti do ozbiljnih komplikacija ukoliko se ne leči adekvatno. Među njima, orbitalne komplikacije, poput preseptalnog i orbitalnog celulitisa, subperiostalnog apscesa (SPA), orbitalnog apscesa i tromboflebitisa kavernoznog sinusa, predstavljaju najčešće izazove, često povezane sa gubitkom vida ili intrakranijalnom propagacijom. SPA, iako retka, ozbiljna je komplikacija kod dece, koja se javlja usled širenja infekcije u subperiostalni prostor, obično zahvatajući etmoidalne sinuse, usled specifičnih anatomskih i imunoloških razloga. Pravovremena dijagnoza i intervencija ključni su za sprečavanje dugoročnih posledica.

Prikaz slučaja: Prikazujemo slučaj četrnaestogodišnjeg dečaka sa komplikacijama ABRS, uključujući progresivno oticanje desnog kapka i ograničenu pokretljivost oka. Radiološka dijagnostika je pokazala prisustvo SPA, neposredno u regiji desnog etmoidalnog sinusa, uz kompletnu zasenčenost desnog etmoidalnog i maksilarnog sinusa, razaranje koštanih gredica ćelija etmoidalnog labirinta i lamine papiracee, ali bez endokranijalne propagacije procesa. Laboratorijski nalazi su ukazali na povećan broj leukocita, povišen C-reaktivni

protein (CRP), kao i prethodnu izloženost citomegalovirusu i Epstein-Barr virusu sa izmerenim vrednostima imunoglobulina G višim od 500,00 IU/mL. Pogoršanje opšteg stanja pacijenta, uprkos inicijalnoj antibiotskoj terapiji, koja se sastojala od amoksicilina sa klavulonskom kiselinom i metronidazola, sugerisalo je promenu antibiotske terapije i hiruršku intervenciju. Endoskopska hirurgija sinusa (EHS) uspešno je uklonila gnojni sadržaj iz SPA, kao i iz etmoidnog i maksilarnog sinusa. Postoperativno je primenjena kombinacija intravenjskih antibiotika širokog spektra, uključujući vankomicin, meropenem i klindamicin, kako bi se delovalo na potencijalno rezistentne mikroorganizme. To je rezultiralo gotovo potpunom rezolucijom simptoma.

Zaključak: SPA, naročito u pedijatrijskoj populaciji, zahteva hitnu i opsežnu terapiju kako bi se izbegle komplikacije opasne po život. Inicijalna terapija uključuje intravenske antibiotike, dok hirurška drenaža postaje neophodna u slučaju odsustva poboljšanja u roku od 48 sati ili ukoliko postoji rizik od gubitka vida. EHS predstavlja bezbednu i minimalno invazivnu metodu za lečenje SPA. Dalja istraživanja su potrebna za procenu prednosti rane hirurške intervencije, s ciljem optimizacije ishoda i smanjenja morbiditeta u pedijatrijskoj populaciji.

Ključne reči: Apsces, Antibakterijski agensi, De-te, Etmoidni sinus, Hirurške procedure u nosu, Rinosinuzitis.

REFERENCES

1. Fokkens WJ, Lund VJ, Hopkins C, Hellings PW, Kern R, Reitsma S, et al. European position paper on rhinosinusitis and nasal polyps 2020. *Rhinology*. 2020; 58 (Suppl S29): 1-464. doi: 10.4193/Rhin20.600.
2. Anosike BI, Ganapathy V, Nakamura MM. Epidemiology and management of orbital cellulitis in children. *J Pediatric Infect Dis Soc*. 2022; 11(5): 214-20. doi: 10.1093/jpids/piac006.
3. Chandler JR, Langenbrunner DJ, Stevens ER. The pathogenesis of orbital complications in acute sinusitis. *Laryngoscope*. 1970; 80(9): 1414-28. doi: 10.1288/00005537-197009000-00007.

4. Gill PJ, Parkin PC, Begum N, Drouin O, Foulds J, Pound C, et al. Care and outcomes of Canadian children hospitalised with periorbital and orbital cellulitis: protocol for a multicentre, retrospective cohort study. *BMJ Open*. 2019; 9(12): e035206. doi: 10.1136/bmjopen-2019-035206.

5. Sciarretta V, Demattè M, Farneti P, Fornaciari M, Corsini I, Piccin O, et al. Management of orbital cellulitis and subperiosteal orbital abscess in pediatric patients: A ten-year review. *Int J Pediatr Otorhinolaryngol*. 2017; 96:72-6. doi: 10.1016/j.ijporl.2017.02.031.

6. Deutsch E, Eilon A, Hevron I, Hurvitz H, Blinder G. Functional endoscopic sinus surgery of orbital subperiosteal abscess in children. *Int J Pediatr Otorhinolaryngol*. 1996; 34(1-2): 181-90. doi: 10.1016/0165-5876(95)01253-2.

7. Goodwin WJ Jr, Weinshall M, Chandler JR. The role of high-resolution computerized tomography and standardized ultrasound in the evaluation of orbital cellulitis. *Laryngoscope*. 1982; 92(7 Pt 1): 729-31.
8. Skedros DG, Haddad J Jr, Bluestone CD, Curtin HD. Subperiosteal orbital abscess in children: diagnosis, microbiology, and management. *Laryngoscope*. 1993; 103(1 Pt 1): 28-32. doi: 10.1288/00005537-199301000-00007.
9. Werner MT, Gottfried JS, Awan BZ, Pollack AZ, Tong CCL, Fastenberg JH, et al. Intracranial and orbital complications of sinusitis: a review of rhinologic and multidisciplinary management principles. *Ear Nose Throat J*. 2025; 1455613251342857. doi: 10.1177/01455613251342857. [Epub ahead of print]
10. Burek AG, Tregoning G, Pan A, Liegl M, Harris GJ, Havens PL. Pediatric orbital cellulitis/abscess: microbiology and pattern of antibiotic prescribing *WMJ*. 2023; 122(1): 52-5.
11. Şahin A, Tanriverdi Kaymaz C, Kara Aksay A, Pekçevik Y, Ekemen Keleş Y, Üstündağ G, et al. Pediatric preseptal and orbital cellulitis: a comparative study of clinical, radiologic, and laboratory features. *Pediatr Infect Dis J*. 2026; 45(3): e70-e74. doi: 10.1097/INF.0000000000005028.
12. Trivić A, Cevik M, Folić M, Krejovic-Trivić S, Rubino S, Micić J, et al. Management of orbital complications of acute rhinosinusitis in pediatric patients: a 15-year single-center experience. *Pediatr Infect Dis J*. 2019; 38(10): 994-8. doi: 10.1097/INF.0000000000002414.
13. Otte BP, Harris JP, Schulte AJ, Davies BW, Brundridge WL. *Fusobacterium necrophorum* orbital cellulitis with intraconal abscess. *Cureus*. 2023; 15(7): e41415. doi: 10.7759/cureus.41415.
14. McDermott SM, Onwuka A, Elmaraghy C, Walz PC. Management patterns in pediatric complicated sinusitis. *Otolaryngol Head Neck Surg*. 2020; 163(4): 814-21. doi: 10.1177/0194599820918832.
15. Teinzer F, Stammberger H, Tomazic PV. Transnasal endoscopic treatment of orbital complications of acute sinusitis: the Graz concept. *Ann Otol Rhinol Laryngol*. 2015; 124(5): 368-73. doi: 10.1177/0003489414558110.
16. Stammberger H. The evolution of functional endoscopic sinus surgery. *Ear Nose Throat J*. 1994; 73(7): 451, 454-5.
17. Santos JC, Pinto S, Ferreira S, Maia C, Alves S, da Silva V. Pediatric preseptal and orbital cellulitis: A 10-year experience. *Int J Pediatr Otorhinolaryngol*. 2019; 120: 82-8. doi: 10.1016/j.ijporl.2019.02.003.
18. Tzelnick S, Soudry E, Raveh E, Gilony D. Recurrent periorbital cellulitis associated with rhinosinusitis in children: Characteristics, course of disease, and management paradigm. *Int J Pediatr Otorhinolaryngol*. 2019; 121: 26-8. doi: 10.1016/j.ijporl.2019.02.037.
19. Cantone E, Piro E, De Corso E, Di Nola C, Settini S, Grimaldi G, et al. Clinical markers of need for surgery in orbital complication of acute rhinosinusitis in children: overview and systematic review. *J Pers Med*. 2022; 12(9): 1527. doi: 10.3390/jpm12091527.

Correspondence to/Autor za korespondenciju

Aleksandar Perić, MD, PhD
Department of Otorhinolaryngology, Military Medical Academy,
Crnotravska 17, 11000, Belgrade, Serbia
Phone: +381 641429161
Email: aleksandarperic1971@gmail.com
ORCID: 0000-0002-8453-7272

ORCID Id:

Danijela Đokić MD, 0009-0002-9730-490X
Aleksandar Milenković MD, 0000-0002-5765-7287
Jelena Sotirović MD, PhD, 0000-0001-9818-0668
Milanko Milojević MD, PhD, 0000-0003-0216-0086
Aleksandar Perić MD, PhD, 0000-0002-8453-7272

How to cite this article: Đokić D, Milojević I, Milenković A, Sotirović J, Milojević M, Perić A. Surgical treatment of pediatric subperiosteal abscess secondary to acute bacterial rhinosinusitis – a case report. *Sanamed*. 2026; 21(1): 67-74. doi: 10.5937/sanamed0-66611.